

HISTOPATHOLOGICAL FEATURES OF RIFAMPICIN INDUCED HEPATOTOXICITY AND ITS MITIGATION WITH AQUEOUS EXTRACT OF STEM BARK OF DARHALDI (*BERBERIS LYCIUM ROYALE*) IN MALE MICE.

Saima Rafique¹, Ayesha Afzal², Ammara Khan³, Aamna Khokhar⁴, Khalida Ajmal⁵, Rashada Farooqi⁶.

Objective: To evaluate the histopathological characteristics of rifampin induced liver toxicity and its mitigation by aqueous extract of stem-bark of Darhaldi (*Berberis Lycium Royale*) in male mice model. **Study Design:** Randomized comparative study, **Place and Duration of Study:** The research work carried out for 30 days from 14th April 2014 to 14 May 2014 at the mice quarters of National Institute of Health (NIH), Islamabad in coordination with Islamic International Medical College (IIMC), Riphah Institute of Pharmaceutical Sciences (RIPS)& Army Medical College (AMC). **Methods:** This research work conducted on fifty six male mice. They were indiscriminately grouped into 4 groups (n=14). Group C: Control group given rodent's food pellet and fresh tap water. Group D: Drug treated group given Rifampicin 50mg/kg BW. Group L.A: Low dose group given low dose aqueous extract of stem bark of Darhaldi + Rifampicin (150mg/kg BW). Group H.A: High dose group kept on high dose aqueous extract of stem bark of Darhaldi + Rifampicin (150mg/kg BW) through gavage tube orally. Two mice were sacrificed to take liver samples for baseline histopathology at zero day. Research progress was assessed by sacrificing two mice at fifteenth day for liver histopathology. All remaining mice sacrificed at the thirtieth day for histopathology of liver. **Results:** Rifampicin produced severe hepatotoxicity manifested by severe steatosis, hepatocytic ballooning & increased inflammatory infiltrates. Aqueous extracts of stem bark of Darhaldi (*Berberis Lycium Royale*) produced hepatoprotective effects in dose dependent manner by reversing steatotic changes, hepatocytic ballooning & high inflammatory infiltrates. **Conclusions:** Aqueous extract of stem-bark of Darhaldi (*Berberis lycium Royale*) manifested superb hepatoprotective activity for rifampicin triggered liver damage in dose dependent manner. **Keywords:** Aqueous extract, Darhaldi, Hepatoprotective, Rifampicin, steatosis, inflammatory infiltrates.

1. Assistant Professor of Pharmacology, Wah Medical College, Wah Cantt,
2. Associate Professor of Pharmacology, Wah Medical College, Wah Cantt,
3. Assistant Professor of Pharmacology, Nawaz Sharif Medical College, University Of Gujrat
4. Assistant Professor of Pharmacology, Islamabad Medical And Dental College Islamabad
5. Associate Professor of Pharmacology, Wah Medical College, Wah Cantt,
6. Assistant Professor of Anesthesiology, Wah Medical College, Wah Cantt,

For correspondence: Saima Rafique¹, Assistant professor of pharmacology department, wah medical college, wah cantt, email; saimarafiqu34@gmail.com

Rafique S¹, Afzal A², Khan A³, Khakhar A⁴, Ajmal K⁵, Farooqi R⁶. **HISTOPATHOLOGICAL FEATURES OF RIFAMPICIN INDUCED HEPATOTOXICITY AND ITS MITIGATION WITH AQUEOUS EXTRACT OF STEM BARK OF DARHALDI (*BERBERIS LYCIUM ROYALE*) IN MALE MICE.** JPUMHS;2020;10(03)135-141.

<http://doi.org/10.46536/jpumhs/2020/10.02.242>

INTRODUCTION:

History of mankind has shown that Tuberculosis (TB) has prevailed as one of the disastrous disease by influencing 10 million people in 2018 resulting in 1.5 million deaths.¹ *Mycobacterium tuberculosis* was the main culprit involved in pathogenesis of the tuberculosis. ² Rifampicin, recently one of the first line anti-tuberculosis regimen, discovered in 1957 and it was proven for its therapeutic use in 1968 due to its marvelous sterilizing activity and shortening treatment span.³ The mechanism of action of Rifampicin is by binding to DNA dependent RNA polymerase and stopping its action. It blocks RNA synthesis of the pathogen *Mycobacterium tuberculosis* ultimately leading to its death.⁴ Although Rifampicin is recognized and used as first line anti-TB agent but it also has a disadvantage of producing hepatotoxicity due to being an enzyme inducer of several metabolic pathways specifically of enzyme system haemoprotein P450 (CYP3A4).⁵ Rifampicin induced liver damage includes disturbance in PPAR γ signalling mechanisms

and oxidative stress.⁶ Medications causing liver toxicity can be portrayed by histopathological findings of liver.⁷ *Berberis lycium Royle* is famed for its hepatoprotective prospective.⁸ The various regional names of this herb are Barberry, Ishkeen, Kashmal, Darhaldi, Sumbloo, & ziarlargay.⁹ Berberine (4.2%) is the major constituent of stem-bark of Darhaldi having hepatoprotective potential.^{10, 11} Darhaldi has great role in diabetic treatment.¹² It has wide implications in many different diseases like abdominal disorders, rheumatism, cough, jaundice, ear & eye infections.¹³ This randomized comparative research was rationalized to inspect the hepatoprotective activity of aqueous extract of stem-bark of Darhaldi (*Berberis lycium Royle*) against rifampicin incited hepatotoxicity in mice in dose-dependent manner by doing histopathology of liver.

Materials and Methods:

This randomized comparative study has been carried out in research institute, National

Institute of Health (NIH), Islamabad after being approved by ethical review committee RARE (Riphah Academy of Research & Education) from 14th April 2014 till 14th May 2014. Male mice used in experiment were having age 5-8 weeks, weight 25-50 grams with normal histology of liver. Mice were housed in NIH under standard environmental conditions at temperature of (22-24°C) and acclimatized for a period of one week.

Animals’ Grouping: Group C: Control group given rodent’s food pellet and fresh tap water. Group D: Drug treated group given Rifampicin 50mg/kg BW. Group L.A: Low dose group given low dose of aqueous extract of stem bark of Darhaldi + Rifampicin (150mg/kg BW). Group H.A: High dose group kept on high dose aqueous extract of stem bark of Darhaldi + Rifampicin (150mg/kg BW) through gavage tube orally.

Aqueous extract preparation:

Bark of the stem of Darhaldi (*Berberis Lycium Royale*) was acquired by Charsadda’s small town, Prang. A famed botanist of Peshawar University Ghulam Jillani authenticated the herb. After washing completely with water, the herb was dried in shade. Dried Darhaldi crushed into fine powder by electric grinder and preserved in plastic jar. Fine Darhaldi powder had been kept soaked in distilled water for continuous 72 hours along with intermittent moving. Soaked Darhaldi powder filtered by Whatmann’s filter paper no.1. Filtrate of Darhaldi was evaporated at 57°C with the help of rotary evaporator in research laboratory of Riphah Institute of Pharmaceutical Sciences (RIPS), Islamabad. Aqueous extract derived from filtrate of Darhaldi was found to be dark brown in color & thick sticky in density. Aqueous extract was stored in air tight glass bottles in refrigerator at 2-5°C for future reference in research. Aqueous extract of Darhaldi was 25% in yield in comparison to original dried herb.¹⁵

Histopathology of Liver:

Liver tissues were dissected out after anesthetizing mice & immediately preserved in 10% formalin for fixation. All liver samples were sent to histopathology lab where they were dried with increasing alcohol concentrations. Liver tissues were further cleared with xylene and impregnated with paraffin. Later on, they were trimmed into four micrometre thin sections by using rotary microtome. They were further stained by using Haematoxylin and Eosin (H&E) dyes and were thoroughly examined under light

microscope. ¹⁶Histological sections of liver tissues were examined & appraised quantitatively as well as qualitatively.

QUALITATIVE EXAMINATION: Qualitatively, Rifampicin induced liver damage was acknowledged by change in color and liver surface texture on naked eye examination

QUANTITATIVE EXAMINATION:

- i) **STEATOSIS:** Hepatic steatosis grading was done according to Kleiner’s criteria.¹⁷ Steatosis was graded as none, mild, moderate and severe under H & E stain as shown in table:1.
- ii) **HEPATOCTIC BALLOONING:** Hepatocytic ballooning grading was done according to Kleiner criteria. ¹⁷ Grading of research observations depicted as None for (score 0), few ballooned cells for (score 1), prominent ballooning in four different fields under 40X objective for (score 2) as shown in table:1.

Overall grade	Steatosis	Ballooning (zone 3)
Mild	1-2	Minimal
Moderate	2-3	Present
Severe	3	Marked

Table 1: A recommended schema for histological grading & staging of non-alcoholic steatohepatitis (NASH) ^(17, 18)

iii) **GRADING OF INFLAMMATION:** Histological Activity Index (HAI) was used to grade inflammation of hepatocytes as shown in table: 2 & 3.

Table 2: A recommended scheme for histological grading & staging of Inflammation.¹⁹

Statistical analysis:

Data analysis done by (SPSS) version 20.0. Mean ± S.D calculated for quantitative

Modified HAI Grading: Necro inflammatory Scores							
Periportal Inflammation (A)	Score	Confluent Necrosis(B)	Score	Spotty Lytic Necrosis, Apoptosis & Focal Inflammation*(C)	Score	Portal Inflammation(D)	Score
Absent	0	Absent	0	Absent	0	None	0
Mild (few portal areas)	1	Focal confluent Necrosis	1	One focus or less per 10x objective	1	Mild, some or all portal areas	1
Mild/moderate (most portal areas)	2	Zone 3 necrosis in some areas	2	2 to 4 foci per 10x objective	2	Moderate, some or all portal areas	2
Moderate (continuous around <50% of tracts or septa)	3	Zone 3 necrosis in most areas	3	5 to 10 foci per 10x objective	3	Moderate/marked, all portal areas	3
Severe (>50% of tracts or septa)	4	Zone 3 necrosis +occasional portal-central(P-C) bridging	4	More than 10 foci per 10x objective	4	Marked, all portal Areas	4
		Zone 3 necrosis + multiple P-C Bridging	5				
		Panacinar or multi acinar Necrosis	6				

*Does not include diffuse sinusoidal infiltration by inflammatory cells.

Grade	Score
Absent	0
Minimal	1-3
Mild	4-8
Moderate	9-12
Severe	13-18

Table 3: A recommended scheme for histological grading & staging of Inflammation¹⁹

histopathological parameters. Percentages & frequencies calculated for histopathological changes. To observe mean differences among control and experiment groups (ANOVA) was applied. Post Hoc Tuckey test was applied to compare mean differences among the groups. P value was calculated by applying Chi square test for comparison of 2 groups. P-value <0.05 labelled as statistically significant.

Results:

A.Gross Examination of Liver:

I) Color of liver:

Color of liver was reddish brown in all (100%) mice in group C, in group LA, in group HA while in group D, color was light brown in 5 (50%) mice and pale yellow in 5 (50%) mice.

All the groups had same color of liver but group D had significantly different color as compared to all other groups ($p < 0.001$).

II) Appearance of liver:

Appearance of liver was fresh and smooth in all (100%) mice in group C, group LA & group HA, while in group D, appearance was greasy in 5 (50%) mice and greasy and granular in 5 (50%) mice. All the groups had same appearance of liver but group D had significantly different appearance as compared to all other groups ($p < 0.001$). Liver appearance was firm in all mice in all of the groups ($p = 1.000$).

B. Microscopic Examination of Liver:

i) Histopathological Qualitative Findings:

In Control group (C), normal histological structure of liver was observed. At magnification power of (20X), liver section was composed of masses of hepatocytes arranged in anastomosing pattern. Liver section of the mouse revealed hepatic lobules. Portal triads were present between adjacent lobules. Portal triads were made up of bile duct, portal vein and hepatic artery. There was branch of the hepatic vein i.e. central vein along the central axis of each lobule. Blood flowing in hepatic artery & portal vein mixes together in hepatic sinusoids and then drains out of lobule through central vein. (Fig-1)

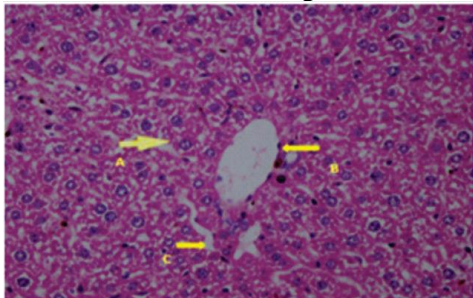


Figure. 1: Photomicrograph of thin section of liver of a mice no. 1 of Group C manifesting [Hepatocyte (A), Central vein (B), Sinusoid space (C)]. H & E Stain, 40 X

Histological examination of thin liver sections in Drug treated group (D) showed disrupted structure. Microvesicular & macrovesicular steatosis was depicted in slide. Macrovesicular steatosis is observed as accumulation of large droplets of fats inside cytoplasm. Whereas microvesicular steatosis is grasped as accumulation of very small droplets of fats inside cytoplasm without hepatocyte nuclear displacement. (Fig.2)

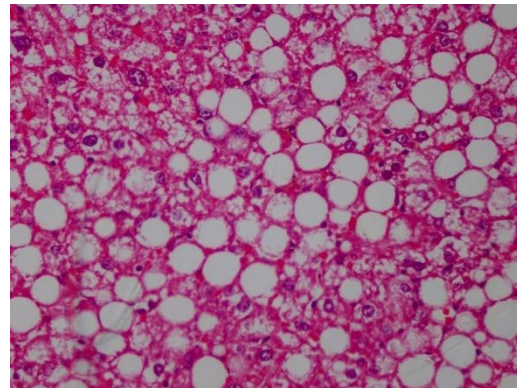
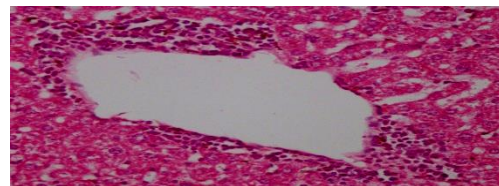


Figure 2: Photomicrograph of liver specimen no. 1 of Drug treated group revealing fat globules (macro vesicular steatosis) demarcated by a circle. H & E Stain, 40X



Hepatocyte ballooning is swelling of hepatocytes with pale cytoplasm leading to lytic necrosis & replacement by inflammatory cells. Hepatocytic ballooning observed strikingly in drug treated group (D). (Fig: 3)

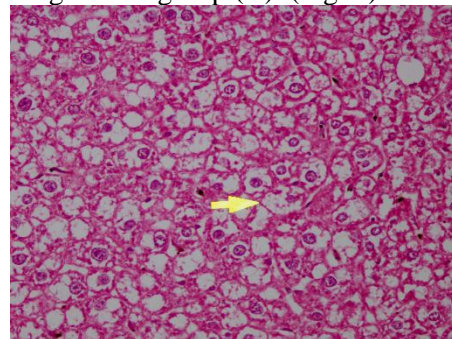


Figure 1: Photomicrograph of liver specimen no. 2 of Drug treated group showing hepatocyte Ballooning Degeneration (A). H & E Stain, 40X

Prominent intralobular inflammation was noticed in drug treated group (D). (Fig 4)

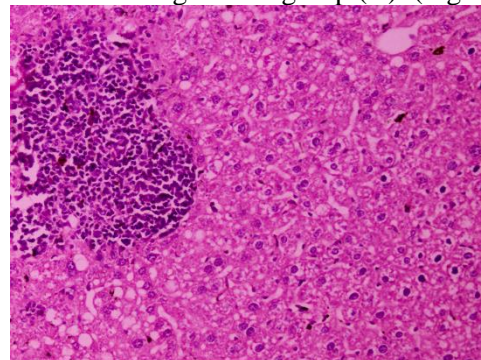


Figure 2: Photomicrograph of section of liver specimen no. 2 of Drug treated group showing focus of intralobular inflammation (A). H & E Stain, 40X

There was severe peri-venular inflammatory infiltrate found in this group. (Fig: 5)

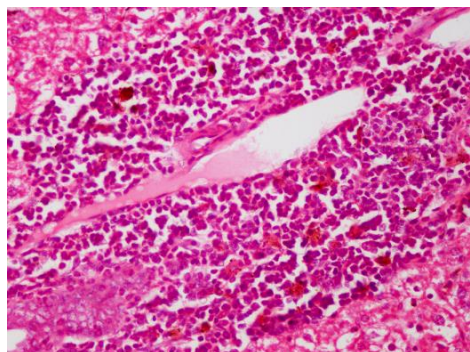


Figure 3: Photomicrograph of liver specimen of Drug treated group displaying severe perivenular inflammation. H & E Stain, 40X

Histological examination of H & E preparations of liver sections of diseased mice of aqueous extract group displayed mild perivenular inflammation, mild intralobular inflammation and mild steatosis in low doses . There was minimum inflammation, steatosis & hepatocytic ballooning in high dose aqueous extract group. (Figure:6 & 7)

Figure 6: Photomicrograph of section of liver specimen of Low aqueous extract treated group showing mild perivenular inflammation. H & E Stain, 40X

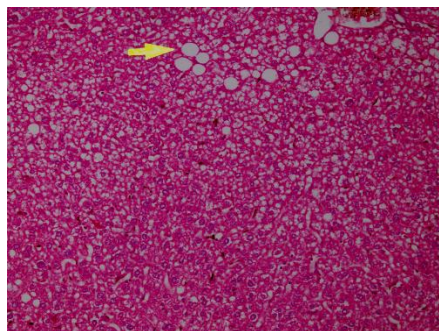


Figure 7: Photomicrograph of liver specimen of High aqueous extract treated group showing minimum steatosis. H & E Stain, 40X

ii) Histopathological Qualitative Findings:

a) Number of fat globules:

Number of fat globules were not normally distributed therefore median and inter-quartile range was described. In group C none of the mice had fat globules. In group D, median fat globules were 5.7 (IQR: 4.45 – 7.62). In group LA, median fat globules were 1.90 (IQR: 0.58 – 3.85). In group HA, median fat globules were 1.55 (IQR: 0 – 2.12). Fat globules found to be significantly high in group D followed by group LA, group HA and group LE (p < 0.001). (Table: 4)

b) Grading of hepatic steatosis:

In group C, fat globules were absent in all (100%) mice. In group D, grade of fat globules was moderate 7 (70%) mice while it was severe in 3 (30%) mice. In group LA, 7 (70%) mice had mild fat globules while 3 (30%) mice had moderate fat globules. Grade of fat globules found to be remarkably high in group D in comparison to all other groups (p < 0.001).

(c) Grading of hepatocytic ballooning:

Grading of hepatocytic ballooning was done among all the groups. In group C all (100%) mice had grade 0. In group D, all (100%) mice had grade 2. In group LA, 8 (80%) mice had grade 1 while 2 (20%) mice had grade 0. Hepatocytic ballooning grade was highest in group D followed by group LA and group HA and this difference was significant (p < 0.001). (Table:1)

(d) Number of Inflammatory infiltrates:

Median inflammation score in group C was 0 (IQR: 0 – 0.25), in group D it was 13.5 (IQR: 11 – 15), in group LA it was 3.5 (IQR: 3 – 5), in group HA it was 2 (IQR: 2 – 3.25). Inflammation score found to be appreciably different in all groups (p < 0.001). (Table-4) It was noted that inflammation was highest in group D and lowest in group C while all other groups had similar inflammation score.

e) Grading of inflammation:

In group C, inflammation was absent in 8 (80%) mice whereas it was minimal in 2 (20%) mice. In group D, inflammation was severe in 7 (70%) mice while it was moderate in 3 (30%) mice. In group LA, 7 (70%) mice had minimal inflammation while 3 (30%) mice had mild inflammation. In group HA, all (100%) animals had minimal inflammation. Grade of inflammation noted to be significantly high in group D in comparison to all other groups (p < 0.001).

Groups	Inflammation Score	No. of Fat Globules
Group C	0 (IQR:0 – 0.25)	0 (IQR: 0 – 0)
Group D	13.5 (IQR: 11 – 15)	5.7 (IQR: 4.45 – 7.62)
Group LA	3.5 (IQR: 3 – 5)	1.9 (IQR: 0.58 – 3.85)
Group HA	2 (IQR: 2 – 3.25)	1.55 (IQR:0 – 2.12)
p-value	< 0.001*	< 0.001*

Table 4: Comparison of Inflammation score & number of Fat Globules between the groups

Values are expressed as Median (IQR)

* = Significant

DISCUSSION:

This randomized comparative study was done to explore the degrees of hepatotoxicity produced by Rifampicin by doing histopathological examination to investigate the hepatoprotective activity of low & high doses of aqueous extract of Darhaldi in male mice. In this research, liver

had greasy appearances & yellow discoloration in drug treated group (D) kept on rifampicin only. Imber in 2002 recorded analogous observations while performing research on hepatic steatosis & its relation to transplantation of liver.²⁰ Steatosis remains hallmark histological characteristic of liver injury produced by drugs. Moderate to severe steatosis was observed in our study in most of the mice group (D) (Figure 2). Comparable findings noted by Hassan in the year 2012 by isoniazid induced liver toxicity in rabbit.²¹ Issabeagloo in 2012 also observed similar results of hepatotoxicity produced in rats by combination of isoniazid & rifampicin.²² Drug produces free reactive oxygen species which leads to severe oxidative stress resulting in hepatic damage.²³

Rifampicin is also an enzyme inducer along with being an anti-tuberculosis drug. It causes induction of many oxidizing enzymes especially of cytochrome P450 (CYP3A4) enzyme system leading to increase oxidative trauma & hepatotoxicity.^(5,6) Tissue damage is mainly caused by free radicals & reactive oxygen species (ROS). Antioxidants are well known to scavenge free oxidative radicals.

Antioxidants are scavenging compounds by nature and play a vital role in reducing oxidative stress to the tissues from free radicals ions.²⁴ Herbal remedies are used since ancient times owing to its numerous health benefits.²⁵ *Berberis lycium Royle* (Darhaldi) is widely known for its hepatoprotective & antioxidant activity.²⁶ Darhaldi is used for different ailments. Berberine is the main constituent of Darhaldi. It is superb for improving the immune system of the body.²⁷ Our research was planned to explore the hepatoprotective potential of low & high doses of aqueous extract of stem bark of Darhaldi in the light of histopathological studies. This study showed that aqueous extract of Darhaldi have promising hepatoprotective potential ($p < 0.001$) in low & high doses.

High dose of aqueous extract (200mg/kg BW) of Darhaldi reverse steatotic changes in experimental groups produced by rifampicin giving evidence of hepatoprotective role.

Hepatoprotective effects of aqueous extract of *Berberis Lycium Royale* (Darhaldi) were also observed by Khan & his colleagues in 2011 while doing experiment in conjunction with Gallium aparine & Pistacia Integerrima in Ccl4 treated rabbits.²⁸

Hepatocytic ballooning remains a crucial criteria to differentiate b/w steatohepatitis & simple steatosis. It stands as chief characteristic of steatohepatitis.²⁹ Kim JH et al in 2017 also observed similar findings while investigating the mechanism of rifampicin-induced liver injury using comparative toxicoproteomics in mice.⁶ This research indicated that aqueous extract of Darhaldi remarkably reversed the hepatocytic ballooning in dose dependent manner.

Extreme inflammation noticed in group (D) given rifampicin only. It showed severe intralobular & perivenular inflammation (Fig: 4 & 5) Our findings are in concordance with the results obtained by Tayal in 2007 while

performing research on Hepatoprotective role of tocopherol against isoniazid & rifampicin induced liver toxicity in albino rabbits.³⁰ Our study proven that aqueous extract of Darhaldi outstandingly reversed back inflammation ($p < 0.001$) in dose dependent manner. (Fig: 6) Similar results were established in the research done on hepatoprotective activity of Berberis Lycium in 6 herbal formulations along with Livokin on hepatotoxicity produced by paracetamol in mice model.³¹

CONCLUSION

The beneficial effect of aqueous extract of stem bark of *Berberis Lycium Royale* (Darhaldi) has been proven in rifampicin incited liver toxicity in male mice and this herb has auspicious role in improving liver histopathology in dose-dependent manner.

LIMITATIONS

Limitations of this study are lack of serum LFT's for comparison. Human research study results are also lacking.

RECOMMENDATIONS

- Serum LFT's should also have been performed for comparison..
- Active components of stem bark of Barberry (*Berberis lycium Royle*) extracts should be secluded and assessed for their hepatoprotective potential.

ACKNOWLEDGEMENTS

We are grateful to Riphah International University, Pakistan for providing financial grant for this research study.

Funding: Riphah International University, Pakistan

Conflict of interest: None declared

Ethical approval: The study was approved by the Institutional Review Committee, IRC

AUTHORS' CONTRIBUTION

Saima Rafique: Literature search, conceptualization of study design, data collection, data analysis and interpretation, write-up.

Ayesha Afzal: Conceptualization of study design and data interpretation.

Ammara Khan: Data collection and analysis.

Aamna khokhar: Conceptualization of study design.

Khalida Ajmal: Data collection and analysis.

Rashada Farooqi: Proof reading

REFERENCES

1. MacNeil A. Global Epidemiology of Tuberculosis and Progress Toward Meeting Global Targets—Worldwide, 2018. MMWR. Morbidity and Mortality Weekly Report. 2020;69.
2. Jagielski T, Minias A, Ingen VJ, Rastogi N, Brzostek A, Zaczek A, et al. Methodological and clinical aspects of the molecular epidemiology of Mycobacterium tuberculosis and other mycobacteria. Clin Microbiol Rev. 2016;29(2):239-90.
3. Grobbelaar M, Louw GE, Sampson SL, van Helden PD, Donald PR, Warren RM. Evolution of rifampicin treatment for tuberculosis. Infection, Genetics and Evolution. 2019 Oct 1;74:103937.

4. Sharma SK, Sharma A, Kadhiraavan T, Tharyan P. Rifamycins (rifampicin, rifabutin and rifapentine) compared to isoniazid for preventing tuberculosis in HIV-negative people at risk of active TB. *Cochrane Database Syst Rev.* 2013;7.
5. Ramappa V, Aithal GP. Hepatotoxicity related to anti-tuberculosis drugs: mechanisms and management. *Journal of clinical and experimental hepatology.* 2013 Mar 1;3(1):37-49.
6. Kim JH, Nam WS, Kim SJ, Kwon OK, Seung EJ, Jo JJ, Shresha R, Lee TH, Jeon TW, Ki SH, Lee HS. Mechanism investigation of rifampicin-induced liver injury using comparative toxicoproteomics in mice. *International journal of molecular sciences.* 2017 Jul;18(7):1417.
7. Devarbhavi H. An update on drug-induced liver injury. *Journal of clinical and experimental hepatology.* 2012;2(3):247-59.
8. Shabbir A, Shahzad M, Arfat Y, Ali L, Aziz RS, Murtaza G, et al. *Berberis lycium Royle: A review of its traditional uses, phytochemistry and pharmacology.* *African Journal of Pharmacy and Pharmacology.* 2012;6:2346-53.
9. Murad W, Ahmad A, Gilani SA, Khan MA. Indigenous knowledge and folk use of medicinal plants by the tribal communities of Hazar Nao Forest, Malakand District, North Pakistan. *Journal of Medicinal Plants Research.* 2011;5:1072-86.
10. Janbaz K, Gilani A. Studies on preventive and curative effects of berberine on chemical-induced hepatotoxicity in rodents. *Fitoterapia.* 2000;71(1):25-33.
11. Girish C, Koner B, Jayanthi S, Rao K, Rajesh B, Pradhan S. Hepatoprotective activity of six polyherbal formulations in paracetamol induced liver toxicity in mice. *Indian Journal of Medical Research.* 2009;129:569-78.
12. Yin J, Zhang H, Ye J. Traditional Chinese medicine in treatment of metabolic syndrome. *Endocrine, metabolic and immune disorders drug targets.* 2008;8:99.
13. Ahmed E, Arshad M, Ahmad M, Saeed M, Ishaque M. Ethnopharmacological survey of some medicinally important plants of Galliyat Areas of NWFP, Pakistan. *Asian Journal of Plant Sciences.* 2004;3:410-5.
14. Pal R, Valphei K, Singh K, Rana S. Garlic confers hepatoprotection in isoniazid rifampicin induced hepatic injury. *Ind J Gastro.* 2003;1:A100.
15. Khan MA, Jehanzeb, Shafiullah, Malik SA, Shafi M. Hepatoprotective effects of berberis lycium, galium aparine and pistacia integerrima in carbon tetrachloride (CCL4)-treated rats. *JPMI - J Postgrad Med Inst.* 2008;22(2):91-4.
16. Anderson G, Bancroft J. Tissue processing and microtomy including frozen. *Theory and practice of histological techniques* London, UK: Churchill Livingstone. 2002:85-107. Kleiner DE, Brunt EM, Van Natta M, Behling C, Contos MJ, Cummings OW, et al. Design and validation of a histological scoring system for nonalcoholic fatty liver disease. *Hepatology.* 2005;41(6):1313-21.
17. Kleiner DE, Brunt EM, Van Natta M, Behling C, Contos MJ, Cummings OW, et al. Design and validation of a histological scoring system for nonalcoholic fatty liver disease. *Hepatology.* 2005;41(6):1313-21.
18. Brunt EM, Janney CG, Di Bisceglie AM, Neuschwander-Tetri BA, Bacon BR. Nonalcoholic steatohepatitis: a proposal for grading and staging the histological lesions. *The American journal of gastroenterology.* 1999;94(9):2467-74.
19. Shiha G, Zalata K. Ishak Versus METAVIR: Terminology, Convertibility and Correlation with Laboratory Changes in Chronic Hepatitis C: INTECH Open Access Publisher; 2011.
20. Imber CJ, St Peter SD, Handa A, Friend PJ. Hepatic steatosis and its relationship to transplantation. *Liver transplantation.* 2002;8(5):415-23.
21. Hassan AS, Ahmed JH, Al-Haroon SS. A study of the effect of Nigella sativa (Black seeds) in isoniazid (INH)-induced hepatotoxicity in rabbits. *Indian journal of pharmacology.* 2012;44(6):678.
22. Issabeagloo E, Taghizadieh M. Hepatomodulatory Action of Camellia sinensis Aqueous Extract against Isoniazid-Rifampicin Combination Induced Oxidative Stress in Rat. *Advances in Bioresearch.* 2012;3(3).
23. Sodhi C, Rana S, Attri S, Mehta S, Yaiphei K, Mehta S. Oxidative-Hepatic Injury of Isoniazid-Rifampicin in Young Rats Subjected to Protein and Energy Malnutrition. *Drug and chemical toxicology.* 1998;21(3):305-17.
24. Agrawal S, Kulkarni G, Sharma V. Antimicrobial and anti-inflammatory activities of bark of four plant species from Indian Origin. 2012.
25. Hoareau L, DaSilva EJ. Medicinal plants: a re-emerging health aid. *Electronic Journal of Biotechnology.* 1999;2(2):3-4.
26. Chand N, Durrani FR, Ahmad S, Khan A. Immunomodulatory and hepatoprotective role of feed-added Berberis lycium in broiler chicks. *Journal of the Science of Food and Agriculture.* 2011;91(10):1737-45.
27. Kim TS, Kang BY, Cho D, Kim SH. Induction of interleukin-12 production in mouse macrophages by berberine, a benzodioxoloquinolizine alkaloid, deviates CD4+ T cells from a Th2 to a Th1 response. *Immunology.* 2003;109(3):407-14.
28. Khan MA, Khan J, Ullah S, Malik SA, Shafi M. Hepatoprotective Effects Of Berberis Lycium, Galium Aparine And Pistacia Integerrima In Carbon Tetrachloride (Ccl4)-Treated Rats. *Journal of Postgraduate Medical Institute (Peshawar-Pakistan).* 2011; 22: 92.
29. Hübscher S. Histological assessment of non-alcoholic fatty liver disease. *Histopathology.* 2006;49(5):450-65.
30. Tayal V, Kalra BS, Agarwal S, Khurana N, Gupta U. Hepatoprotective effect of tocopherol against isoniazid and rifampicin induced hepatotoxicity in albino rabbits. *Indian journal of experimental biology.* 2007;45(12):1031.
31. Girish C, Koner B, Jayanthi S, Rao K, Rajesh B, Pradhan S. Hepatoprotective activity of six polyherbal formulations in paracetamol induced liver toxicity in mice. *Indian Journal of Medical Research.* 2009; 129:569-78.